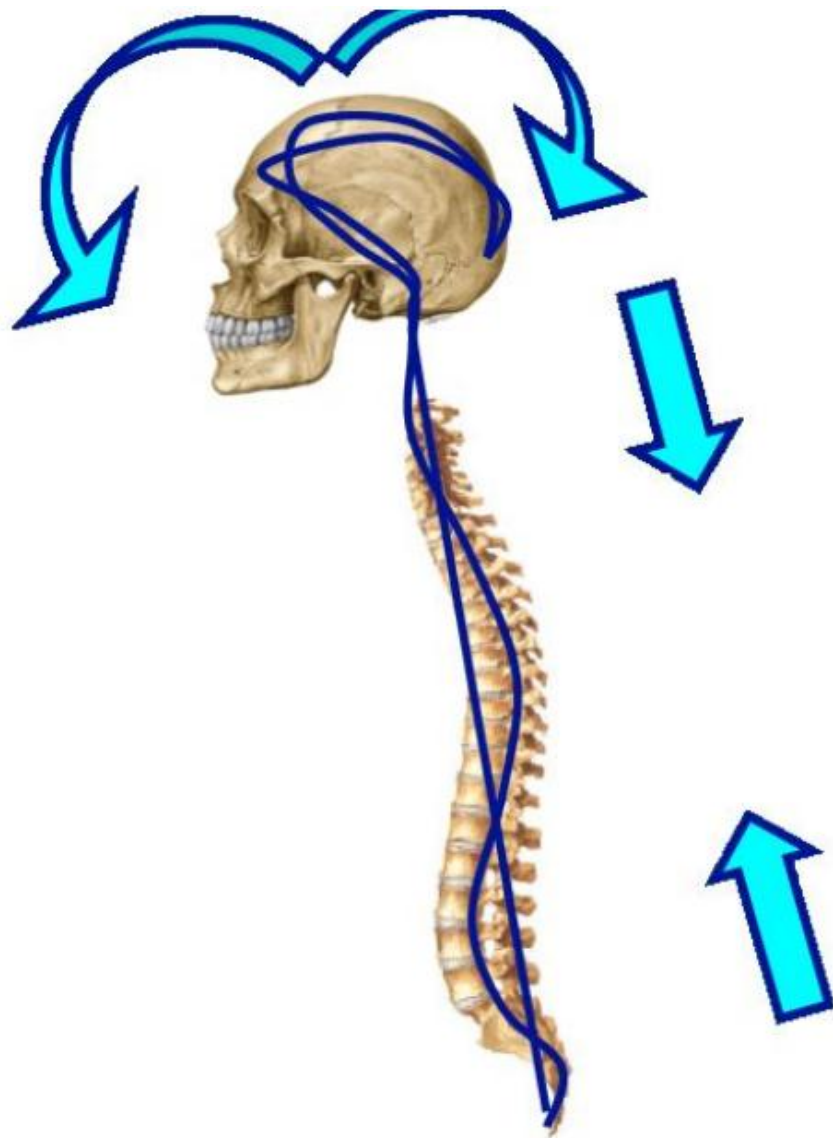
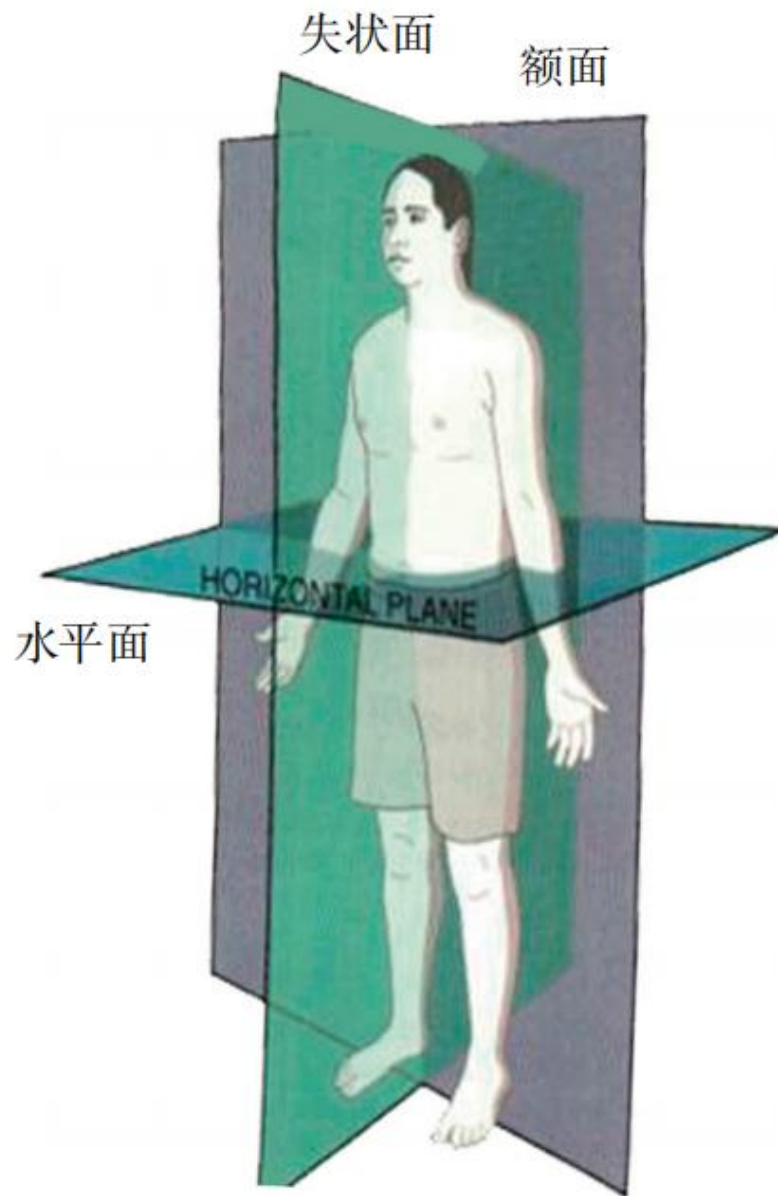


髌骨功能障碍评估与调整

沈亚 PT

- 颅-骶联动





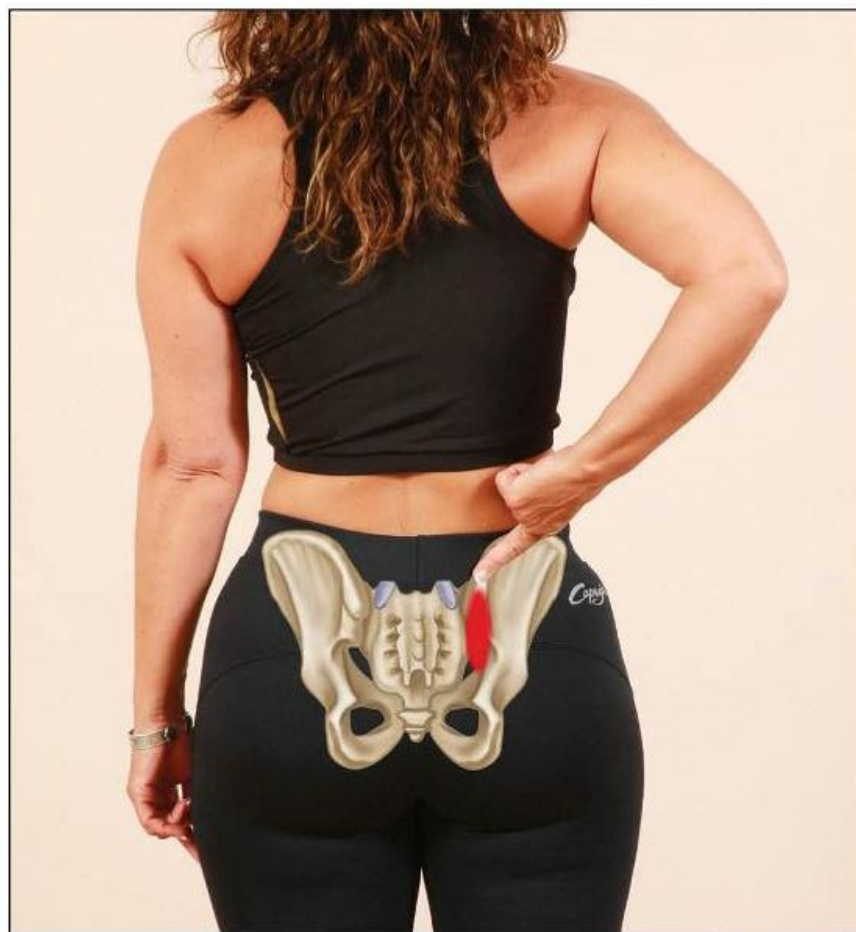
矢状面

额面

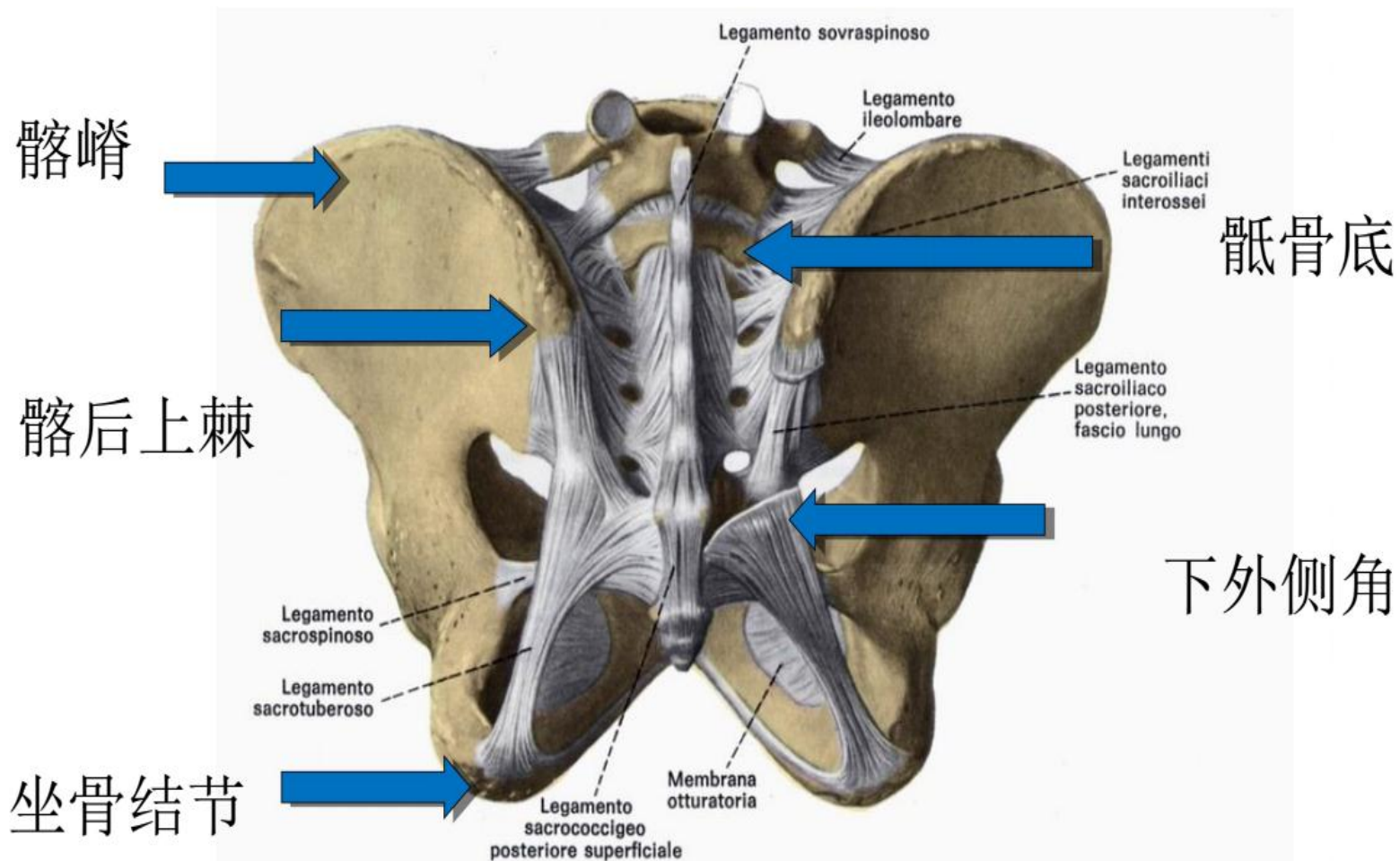
水平面

HORIZONTAL PLANE

骶髂关节疼痛



骨性解剖



骨性解剖


髂嵴



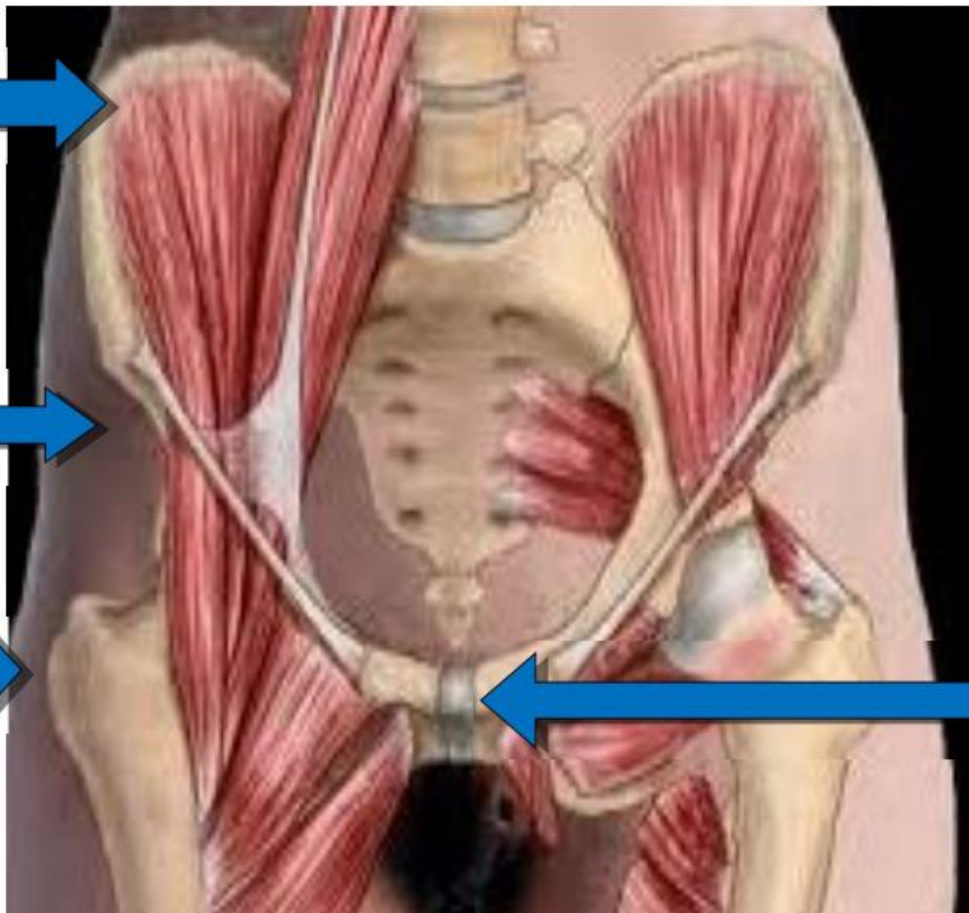
髂前上棘



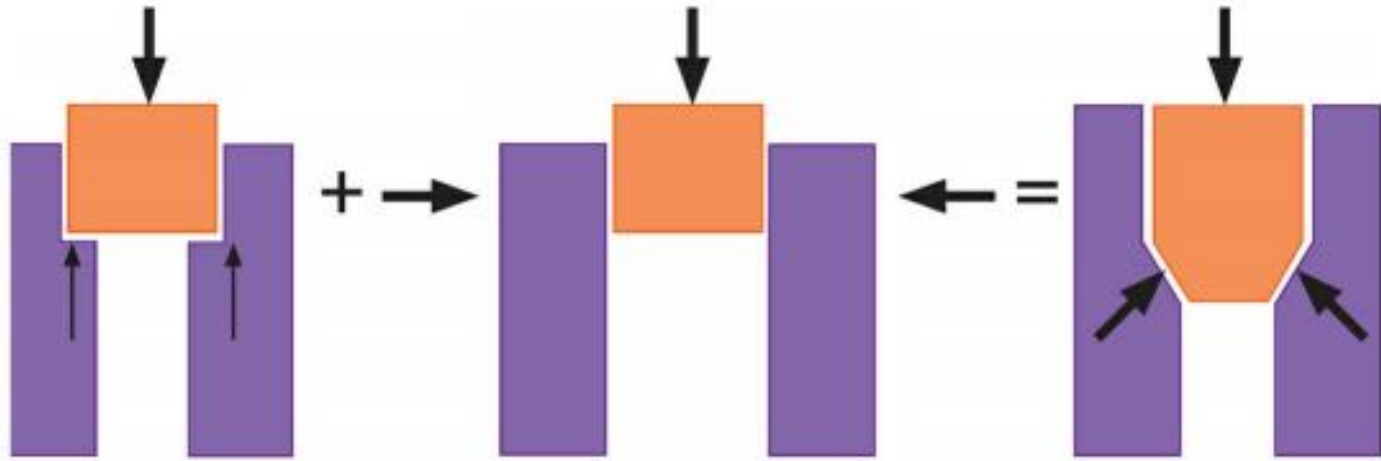
大转子



耻骨



髋髌关节稳定性

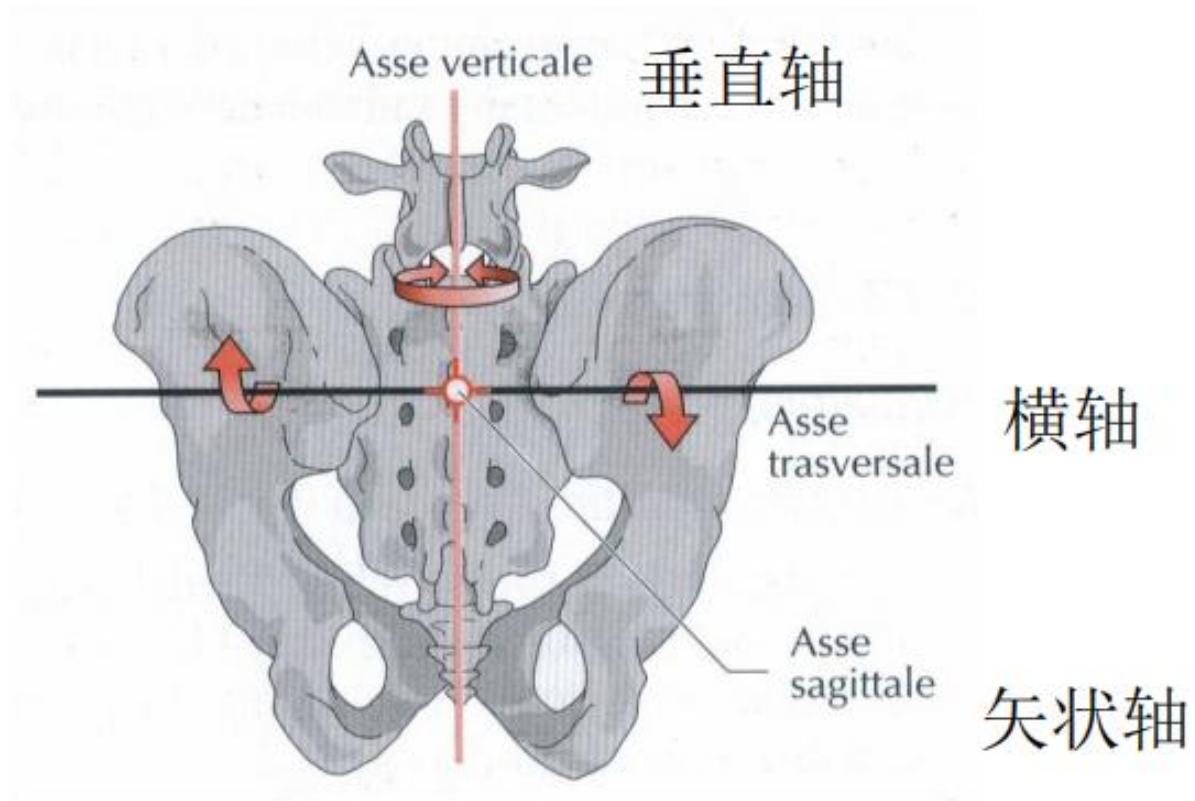


形稳定

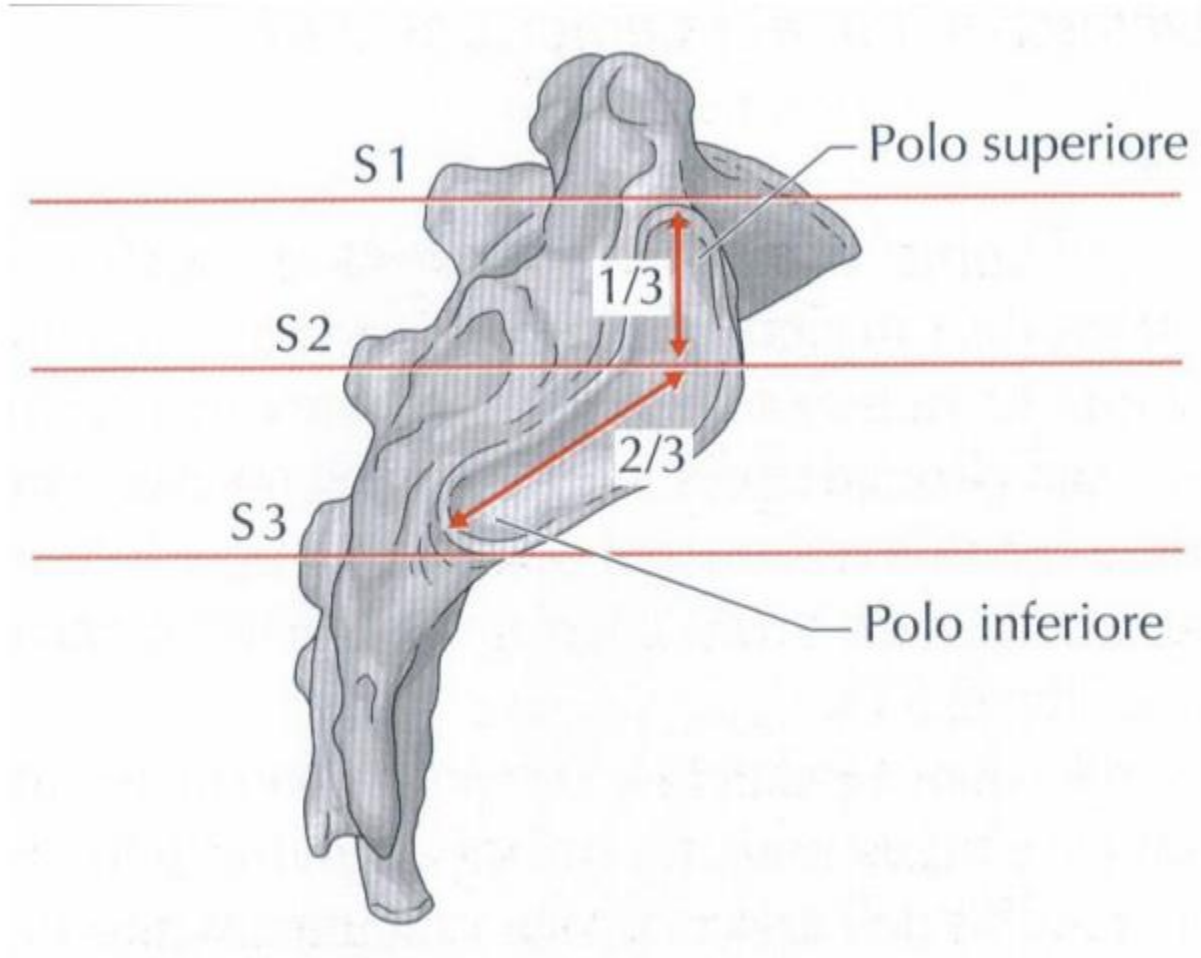
力稳定

髋髌关节稳定性

髋髂关节运动轴

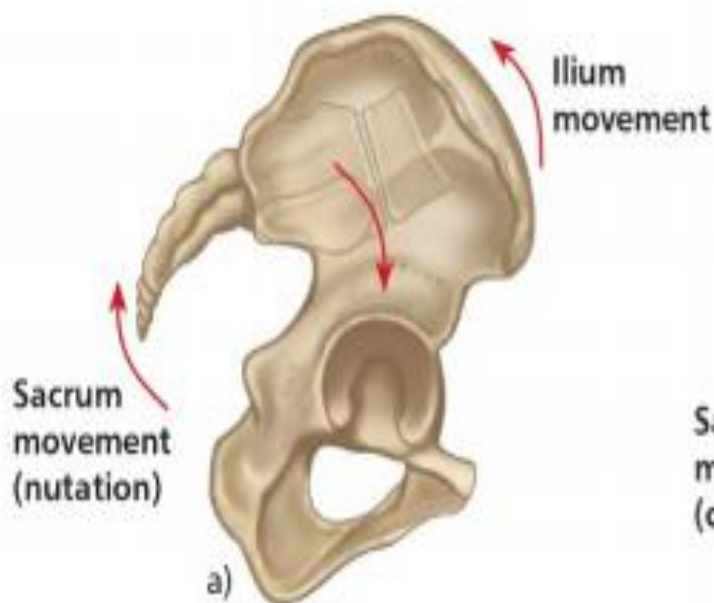


骶骨耳状面

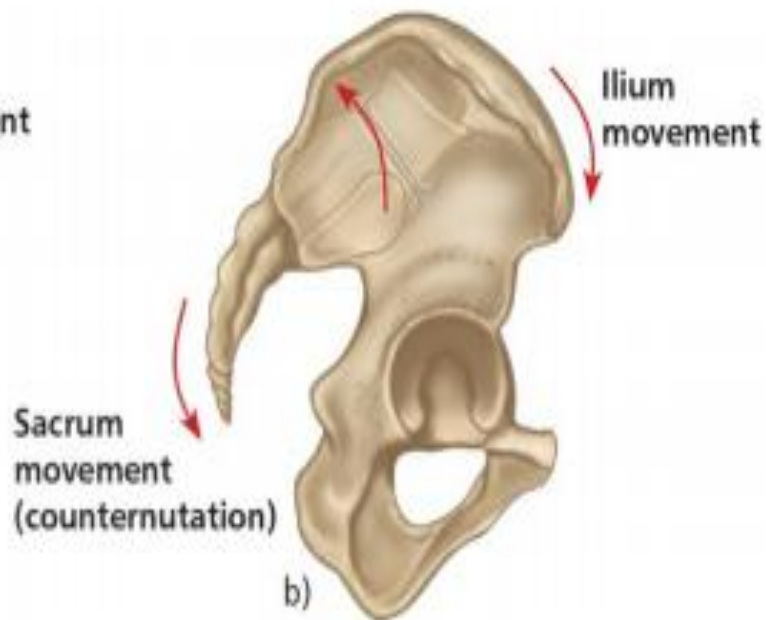


骶髂关节运动

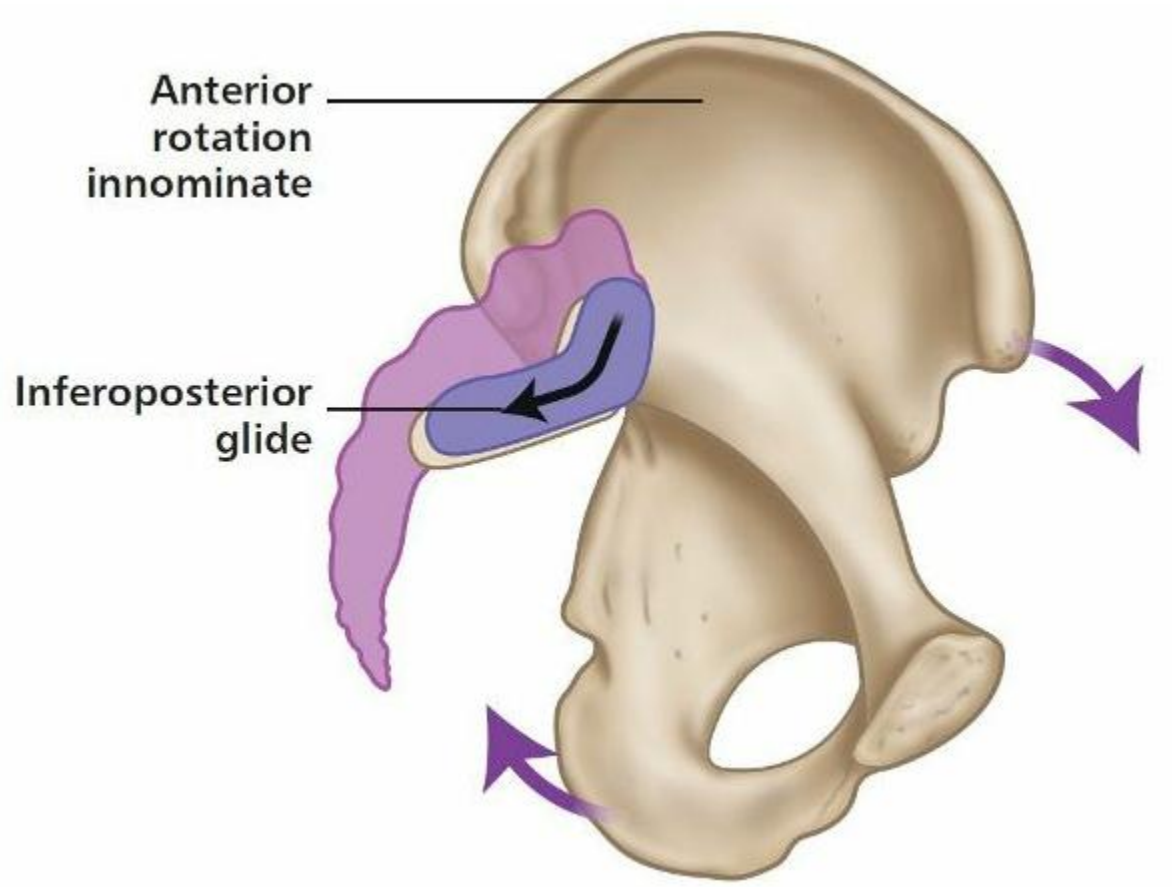
髌骨向后、骶骨
底向前



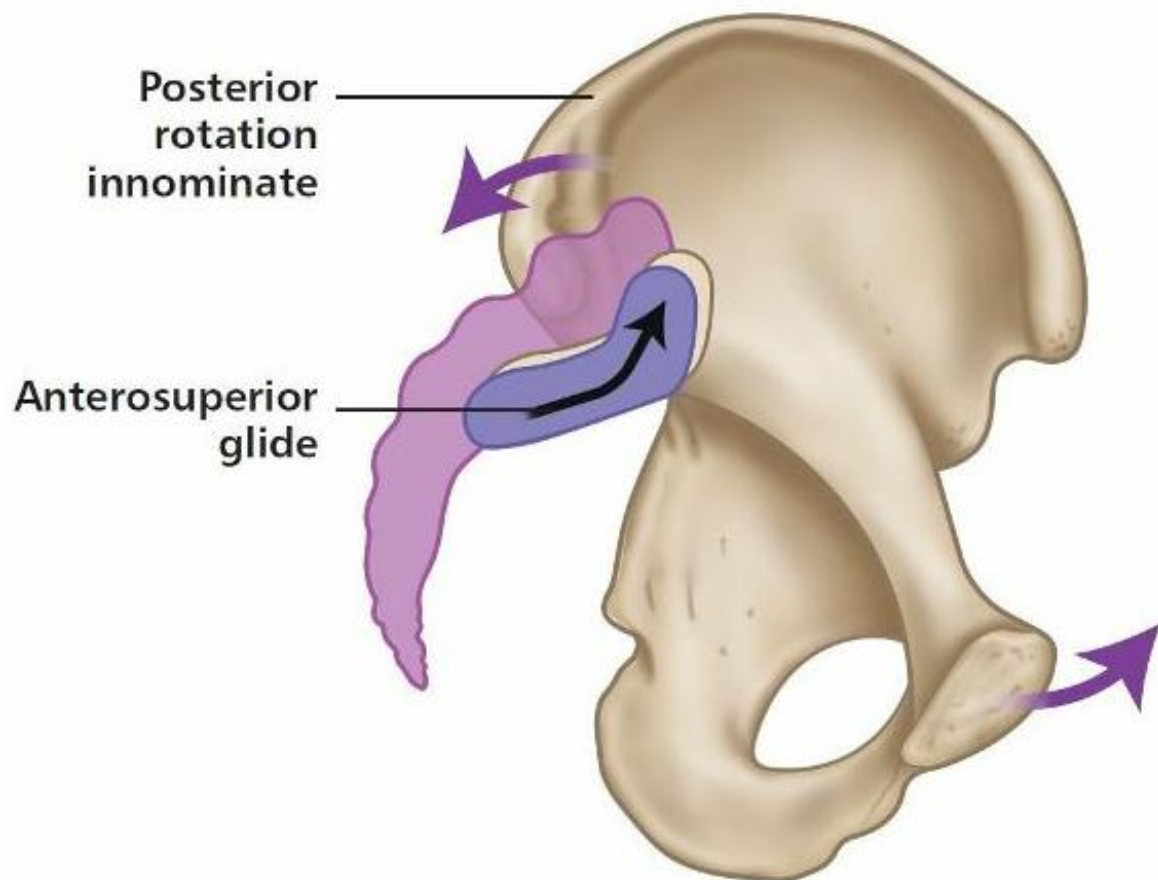
髌骨向前、骶骨
底向后



前髌



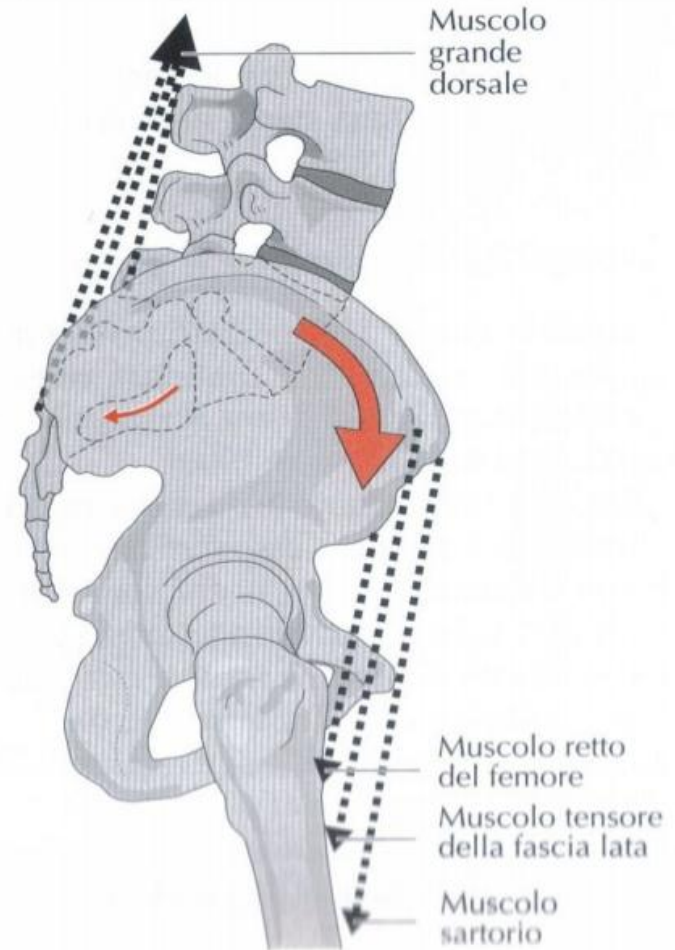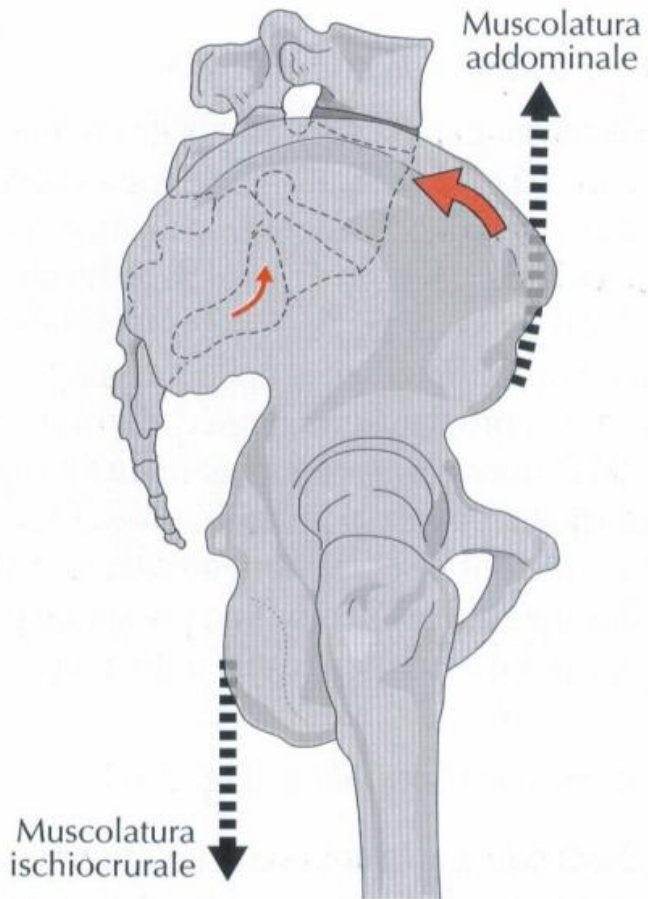
后髌



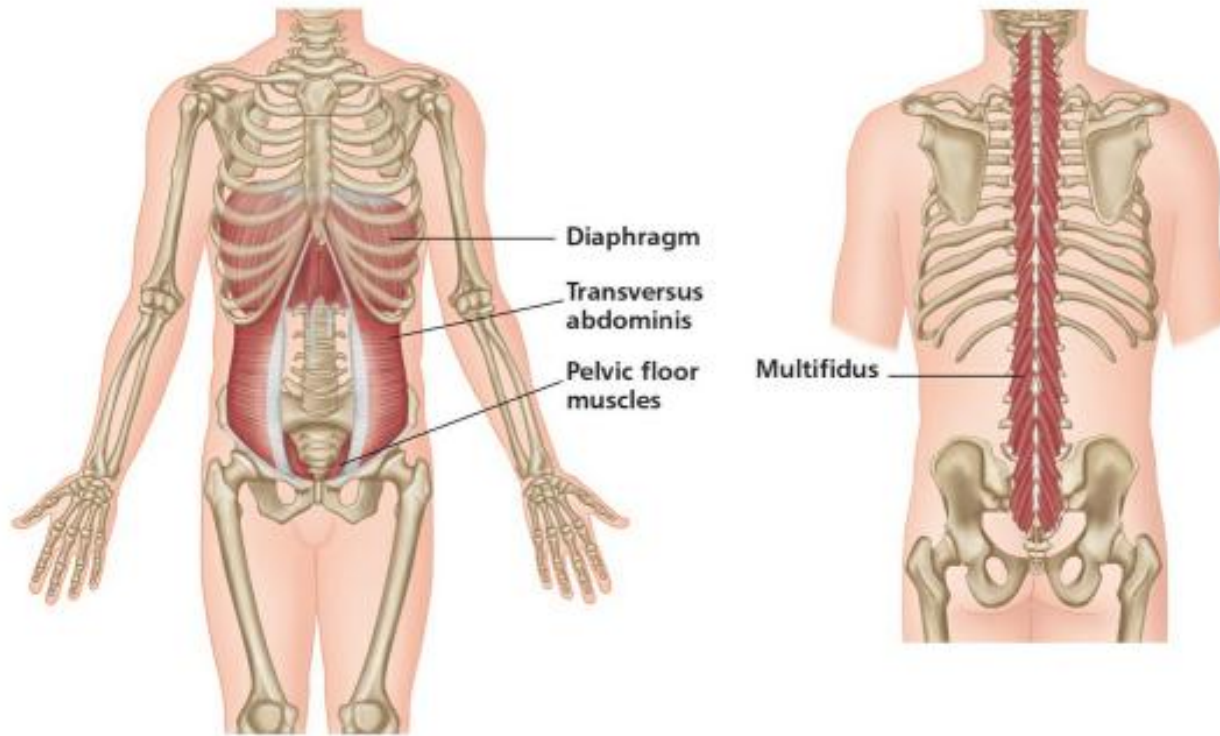
骨盆打开与关闭

- 髋关节内外旋对大、小骨盆开口的影响
- 骶骨运动对大、小骨盆开口的影响

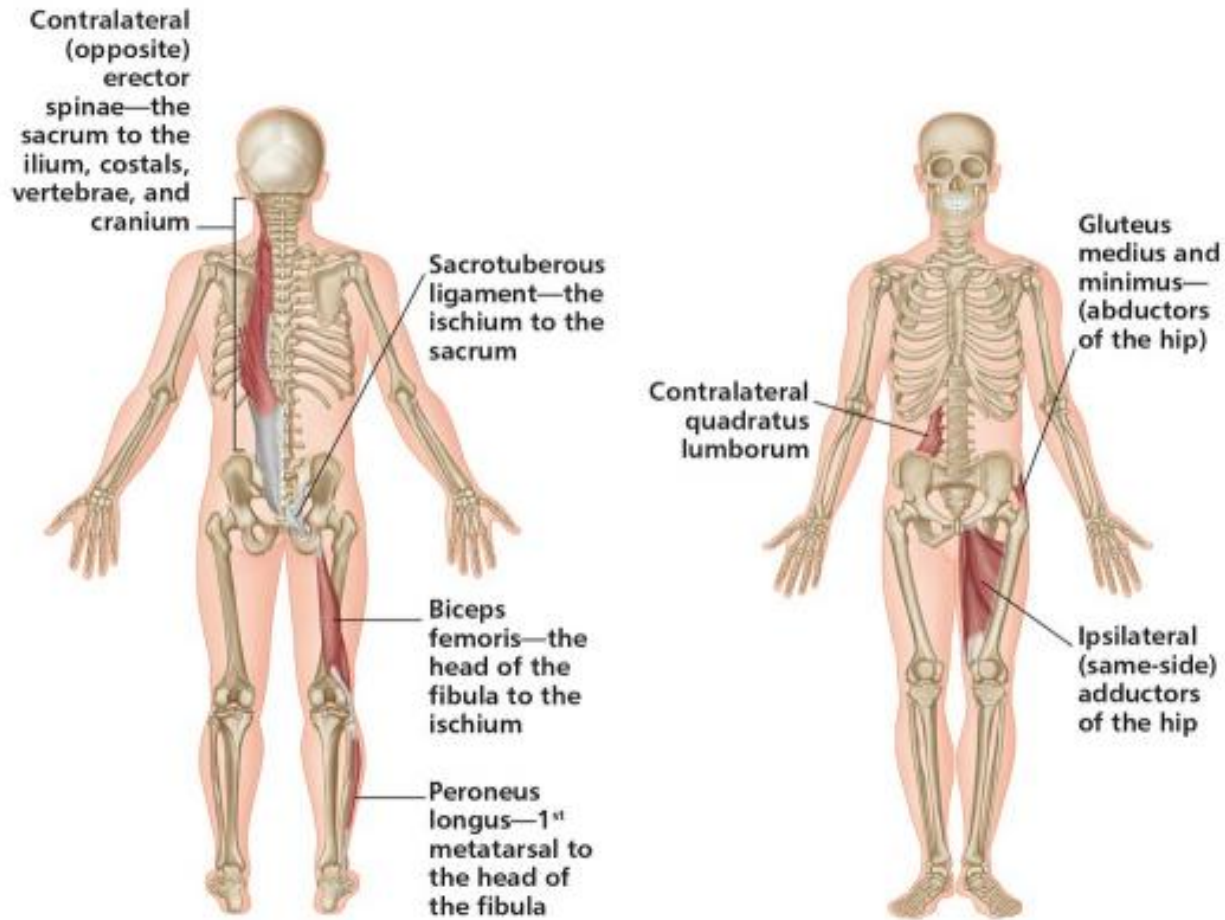
力偶



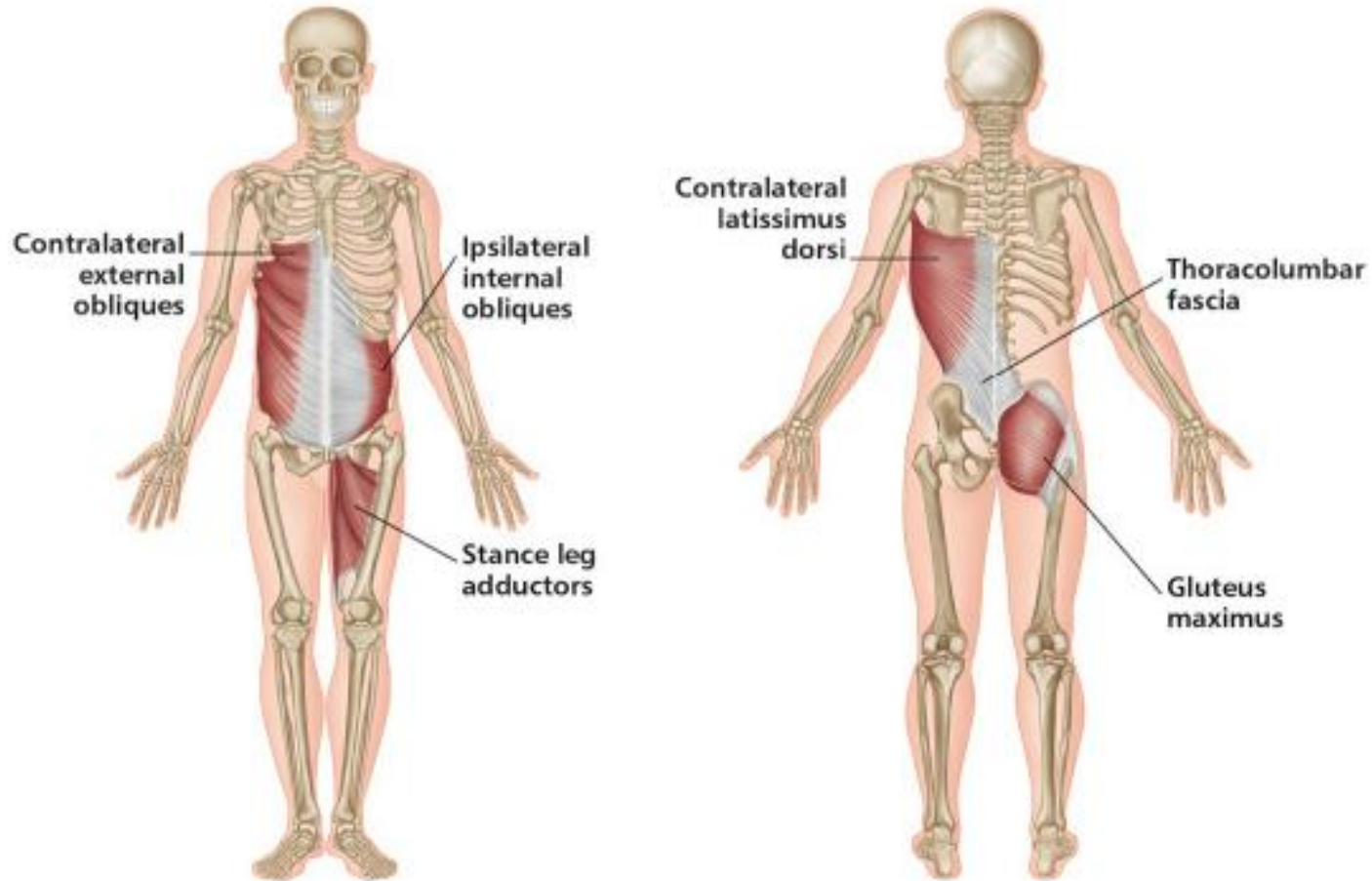
主动机制



主动机制

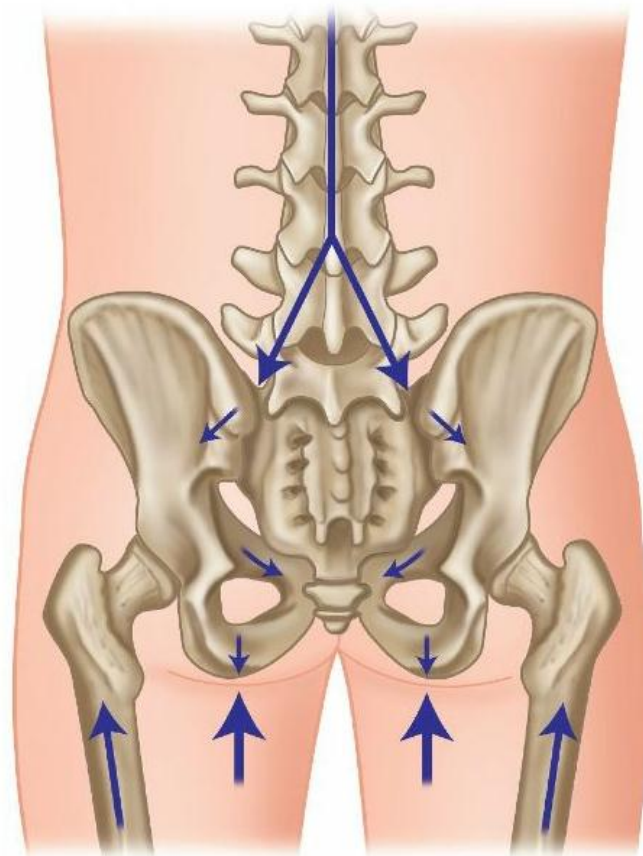
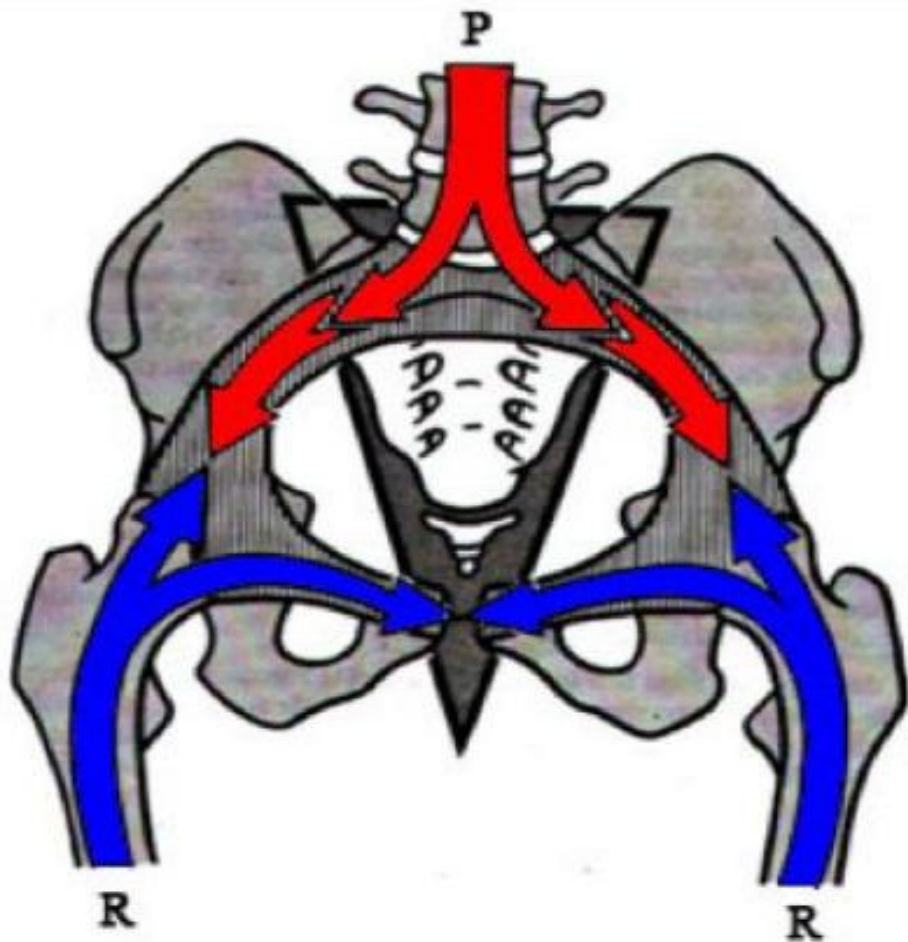


主动机制

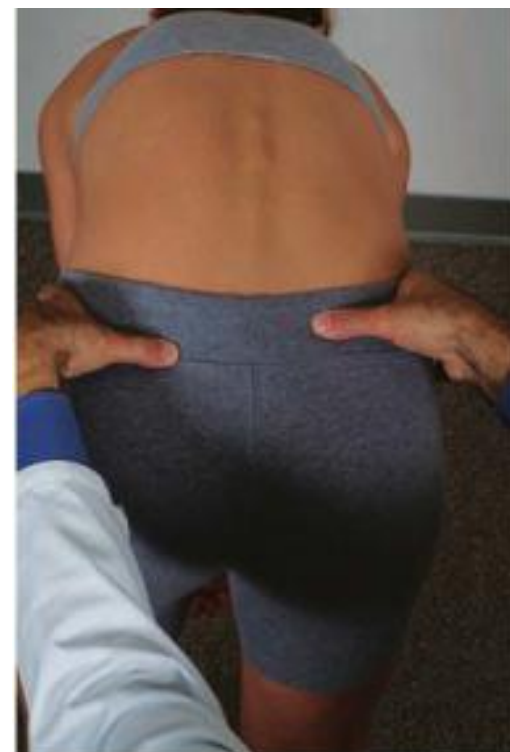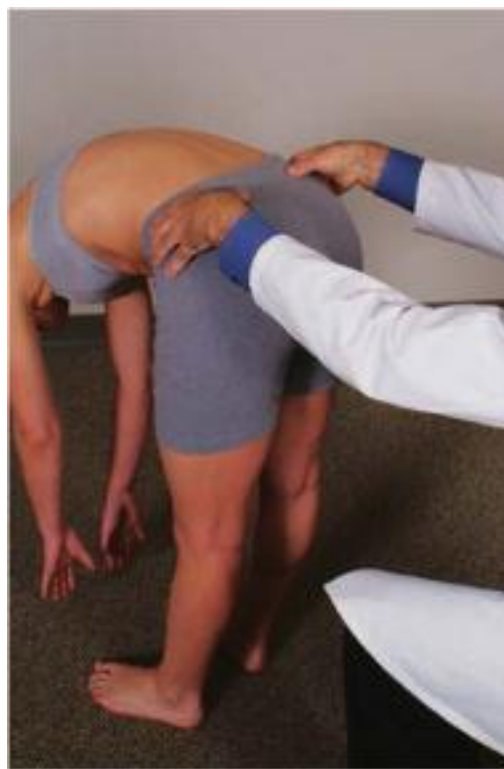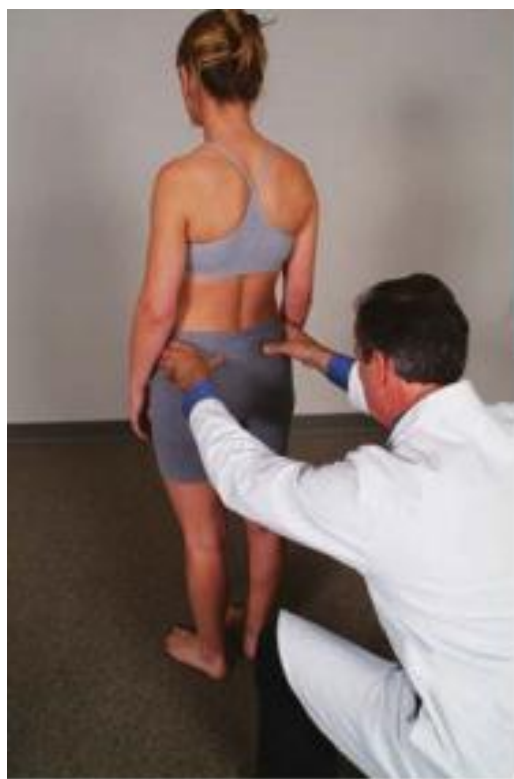


髌骨功能障碍评估...

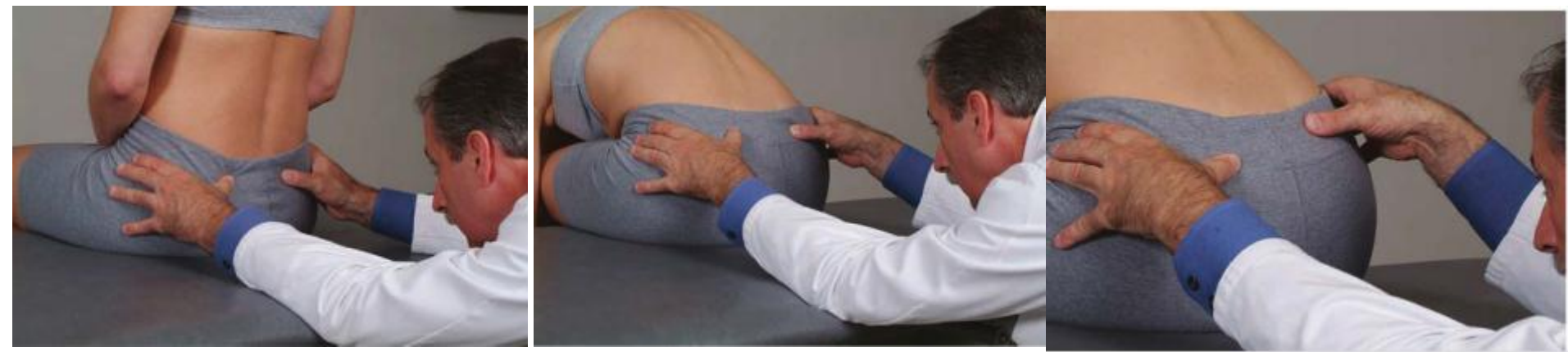
骨盆环



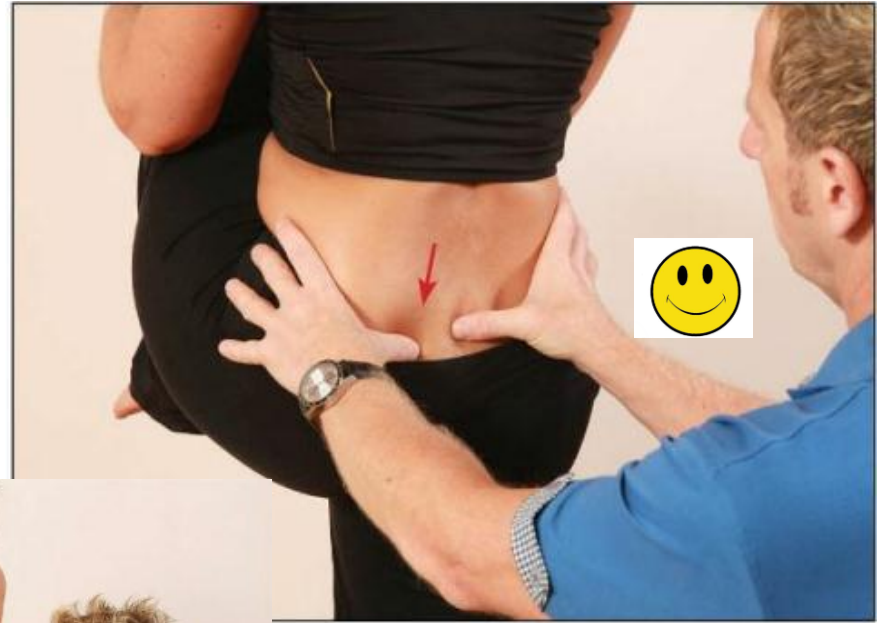
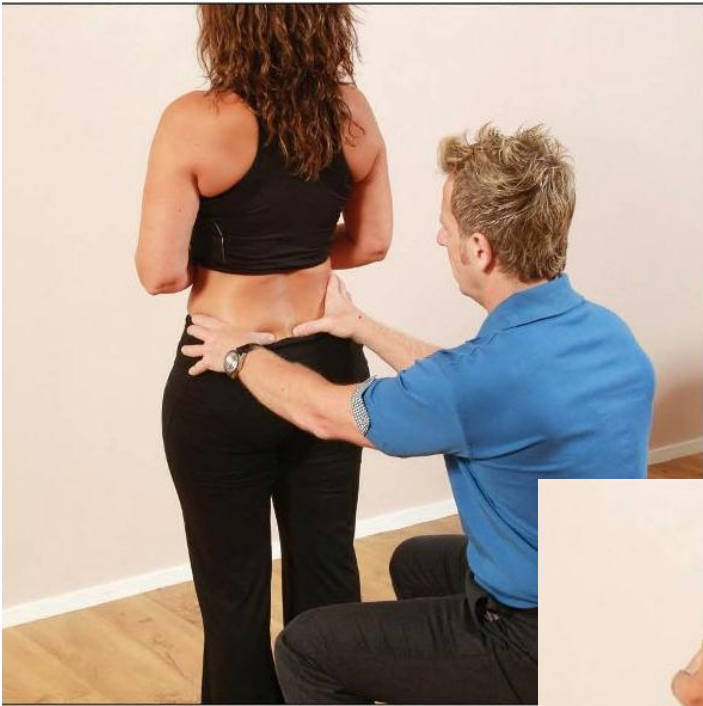
站立位屈曲测试



坐立位屈曲测试



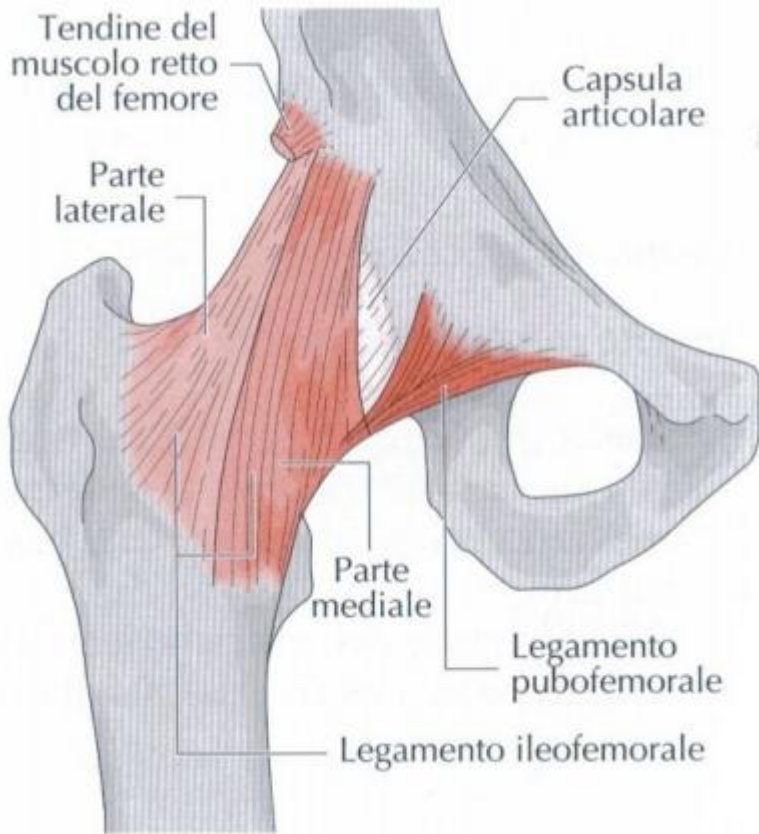单腿支撑测试



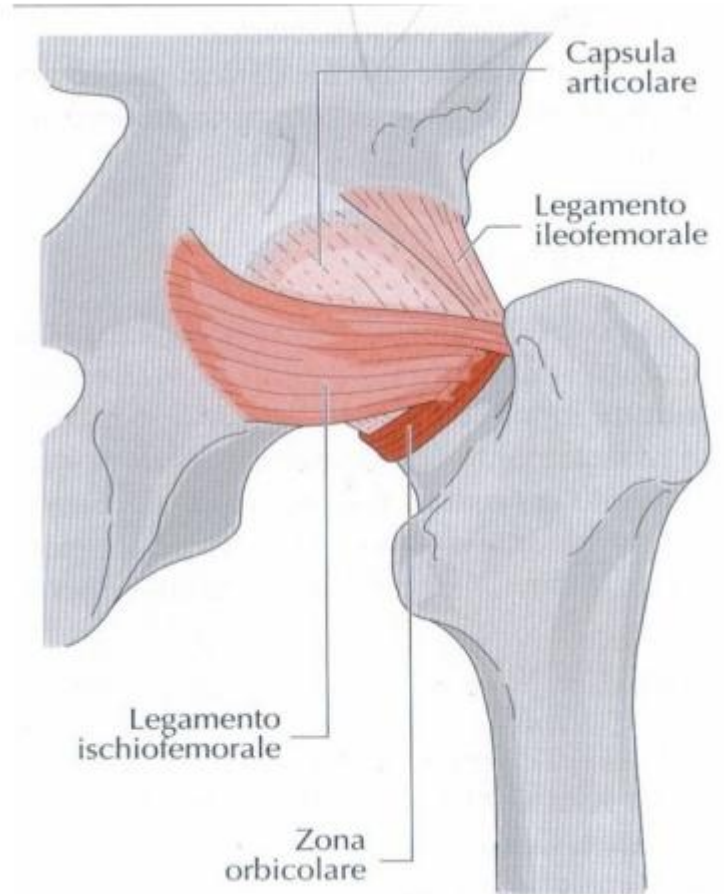
髌骨	测试	骶骨
站立位屈曲测试	非特异性	坐位测试
STORK 测试	特异性	拇指上移

伸长、缩短测试

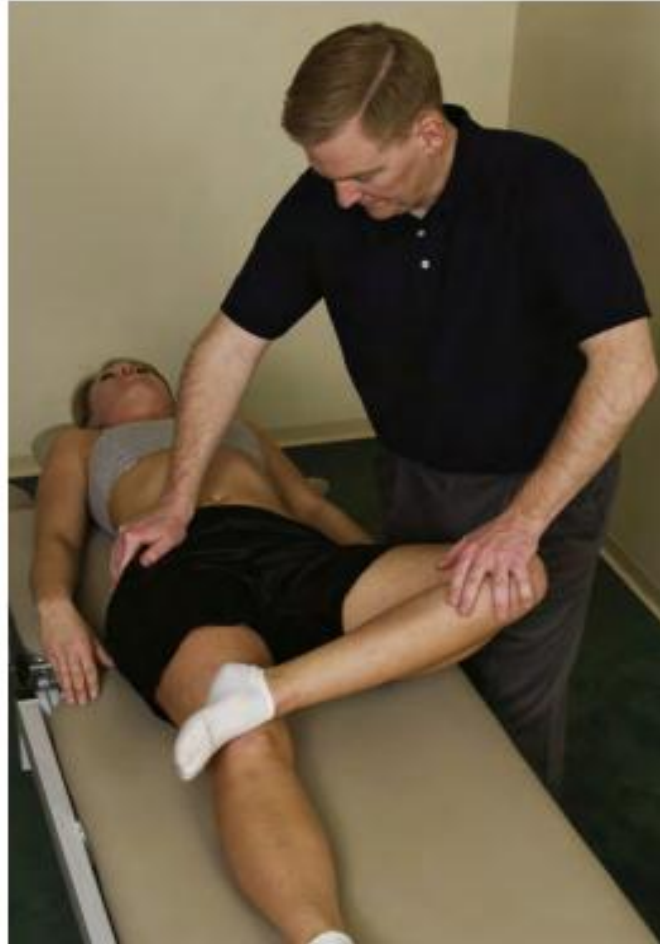髂股韧带



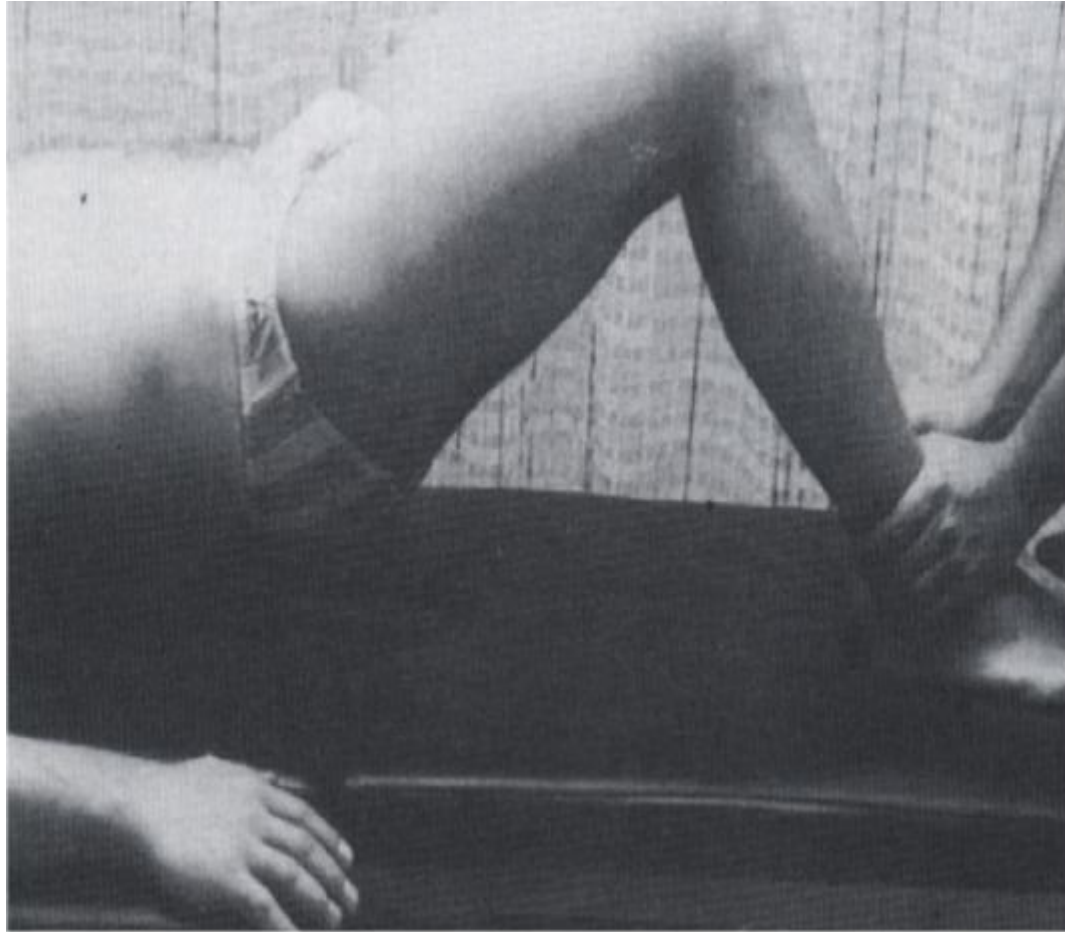
坐股韧带



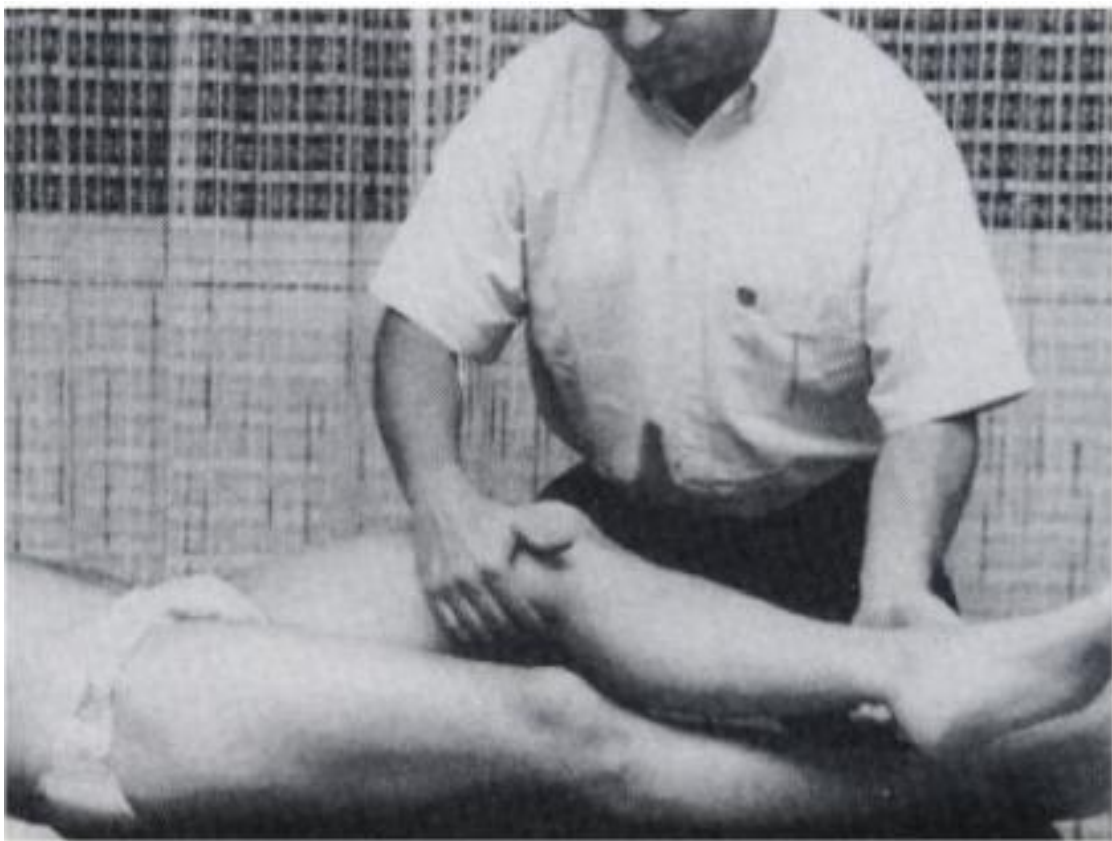“4”字实验



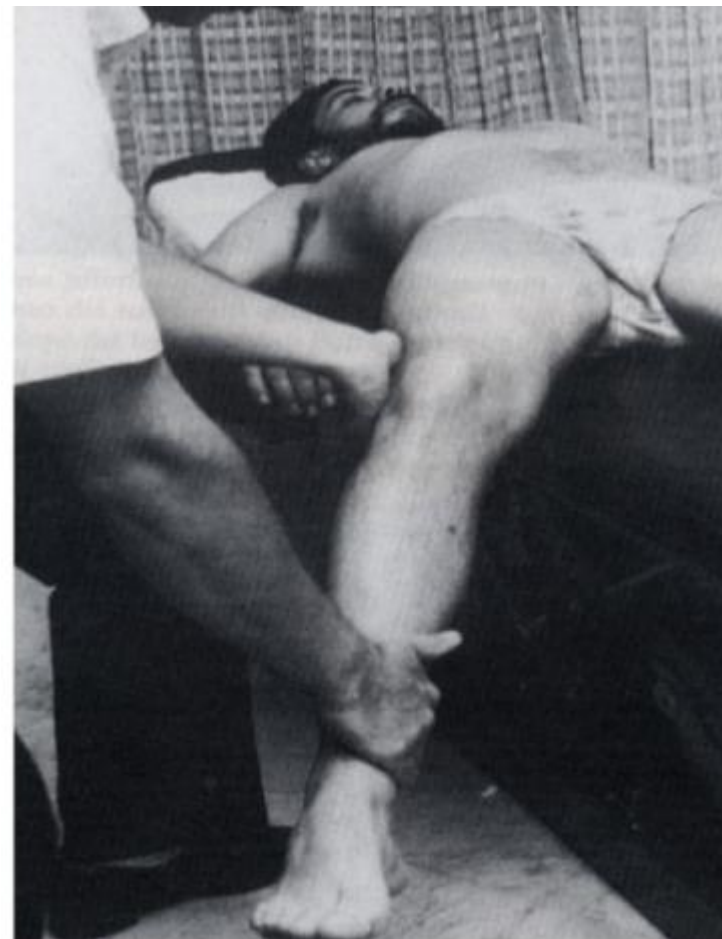骨盆平衡



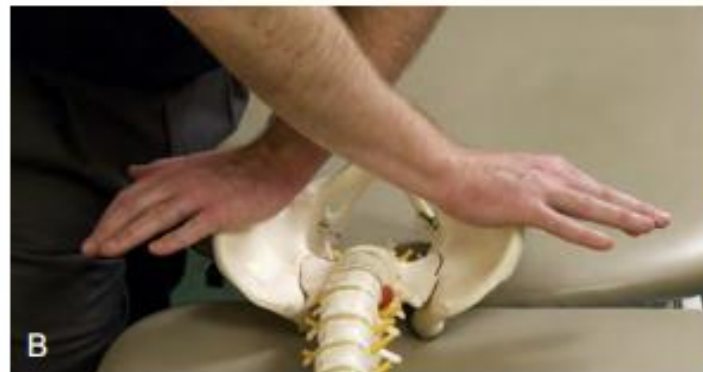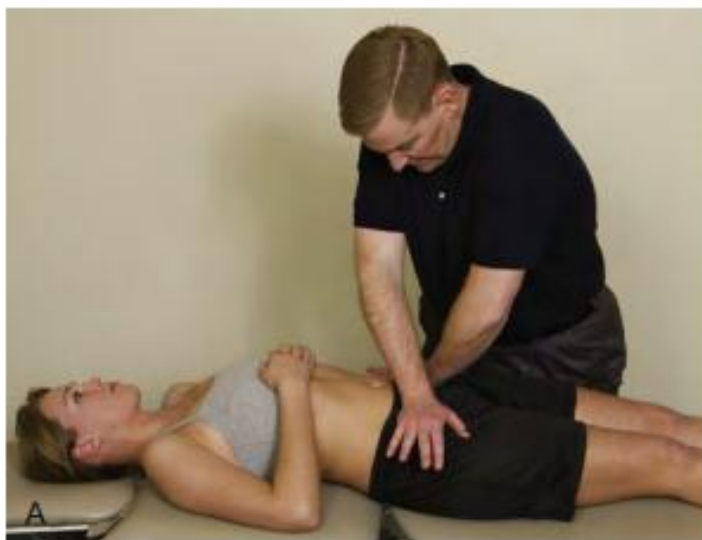伸长实验



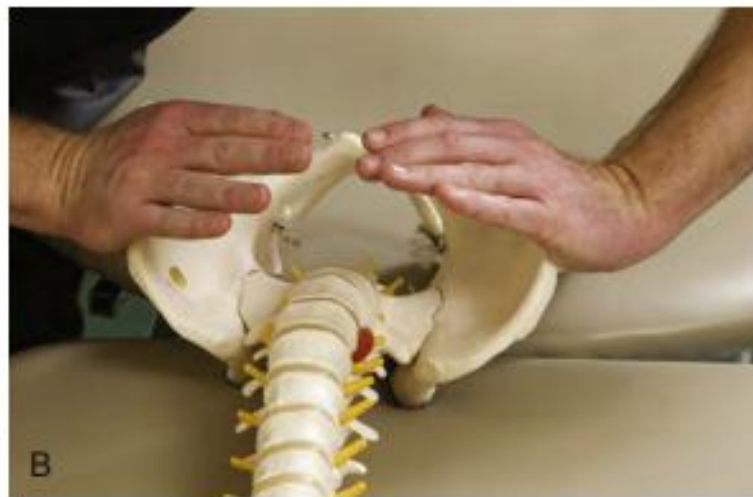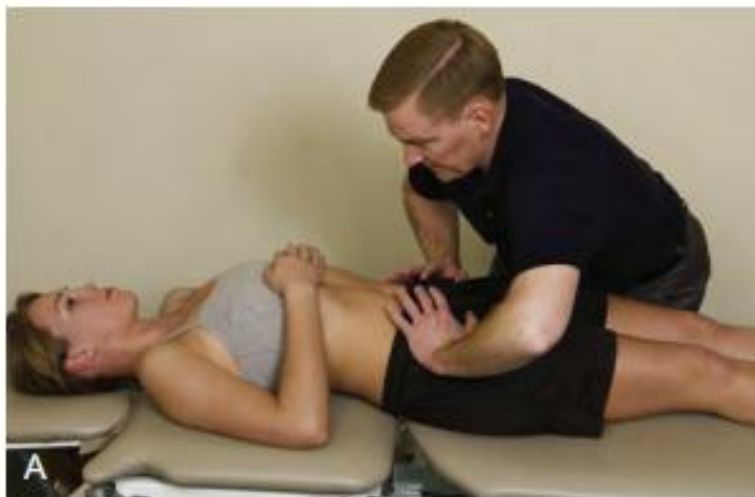缩短实验



髌骨打开评估

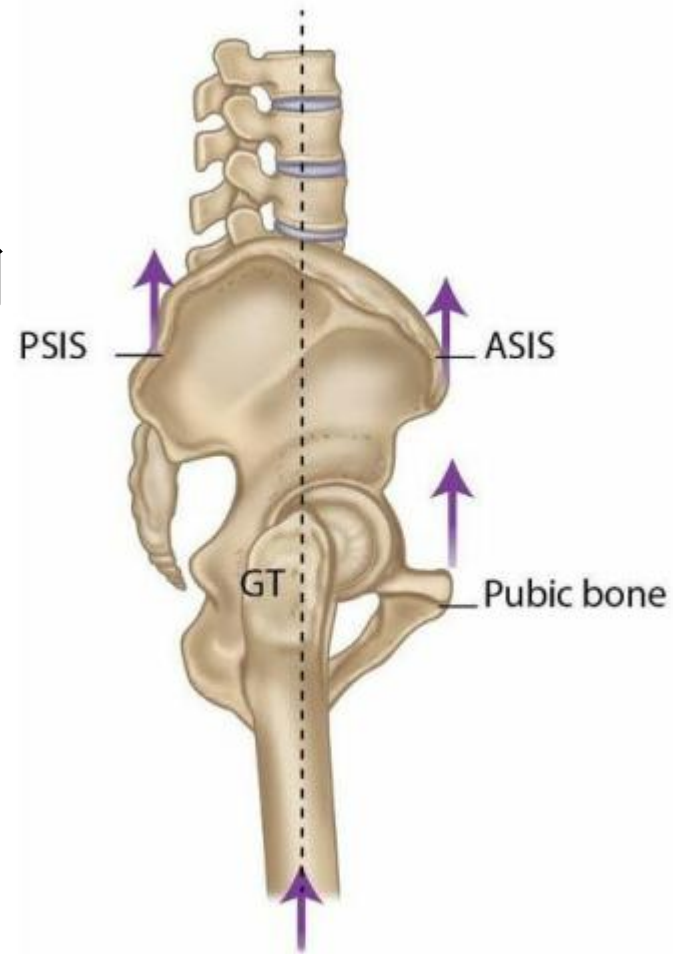


髌骨关闭评估

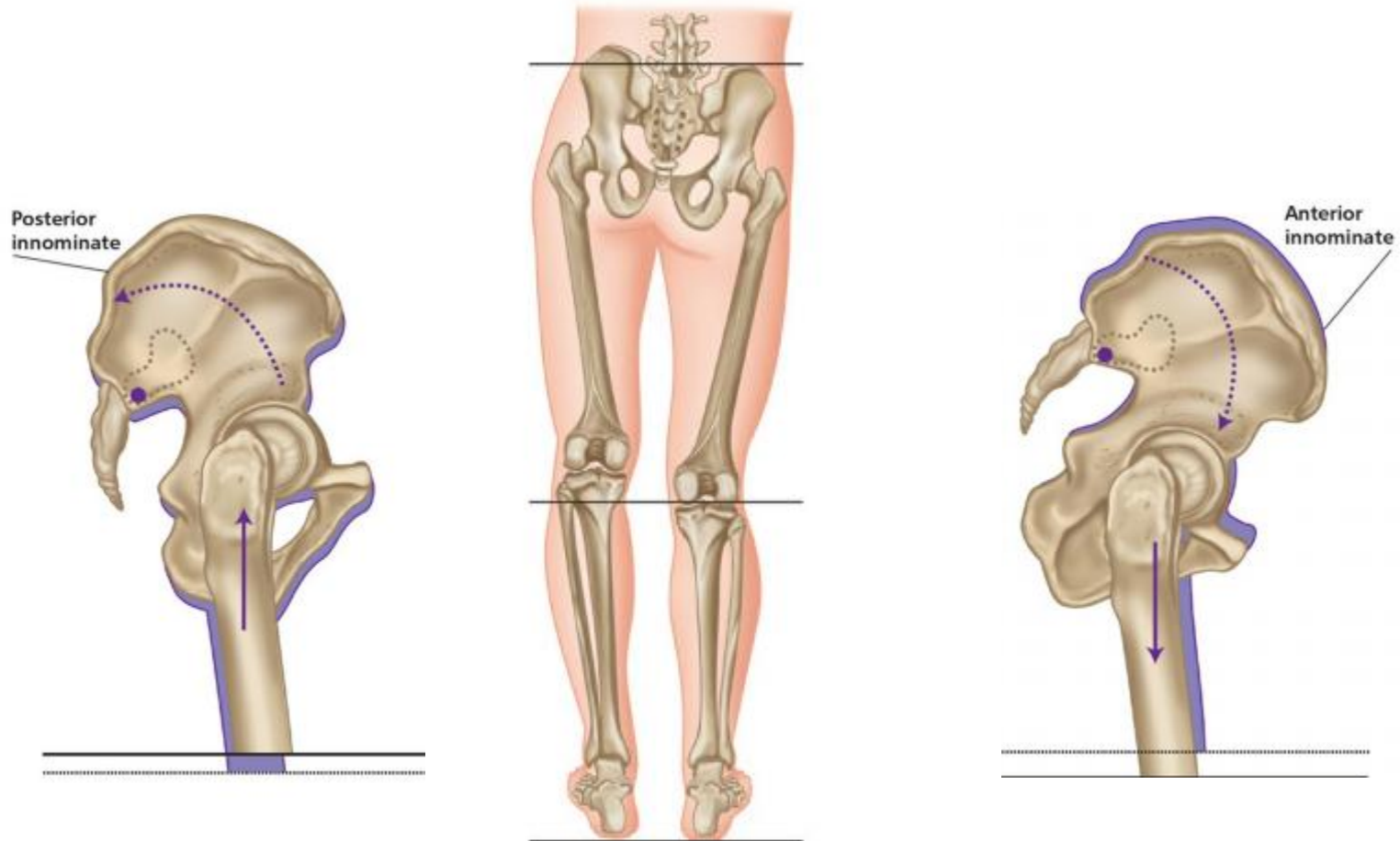


髌骨功能障碍

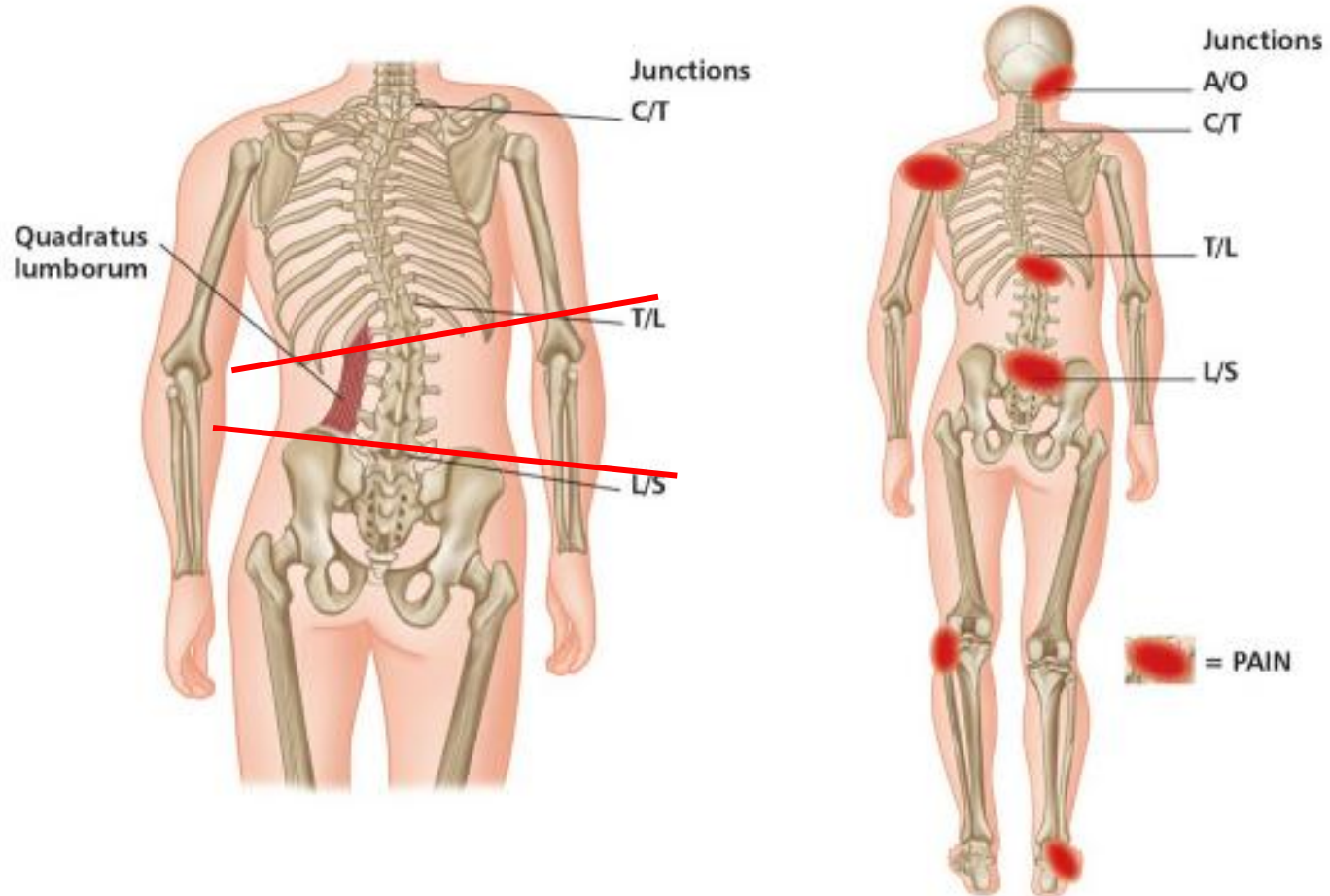
- 生理性功能障碍：前髌、后髌
- 非生理性功能障碍：打开、关闭
- 外伤性功能障碍：上滑、下降



下肢不等长对于骨盆的影响

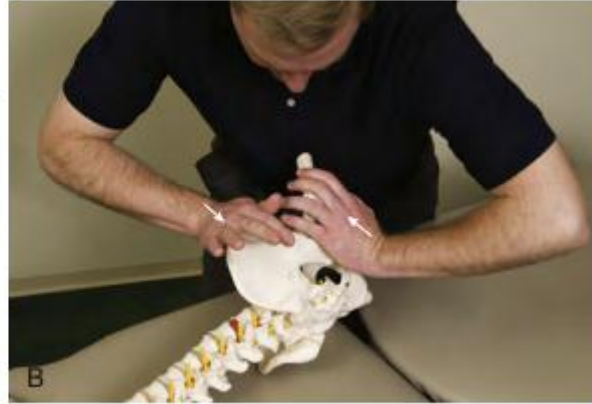
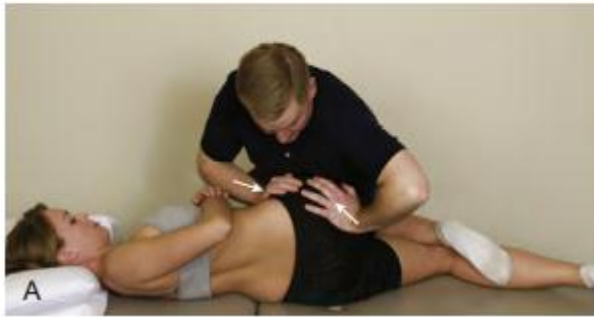
下肢不等长导致的关节疼痛

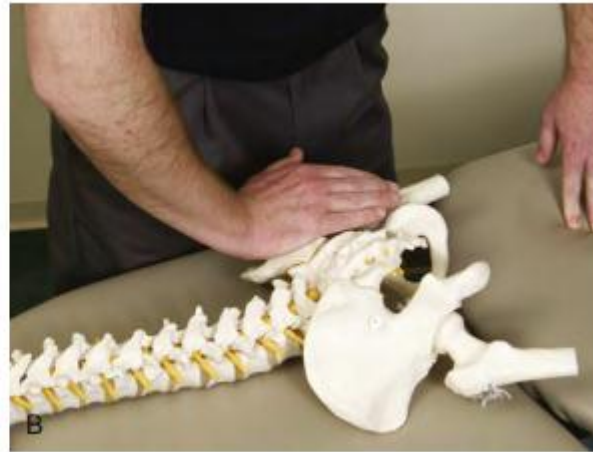
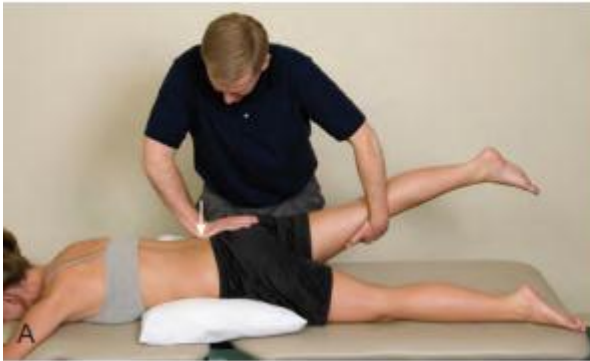
前、后髂调整

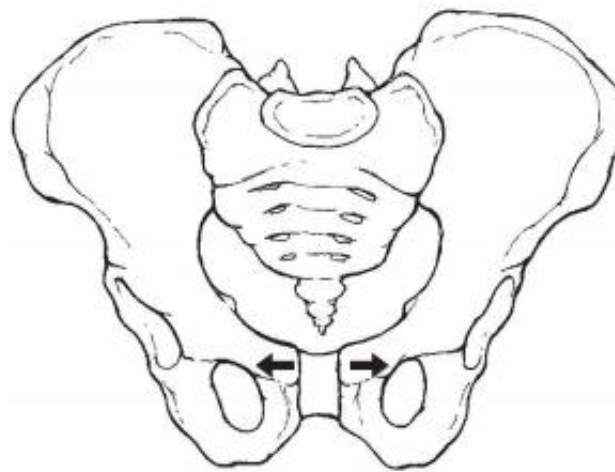
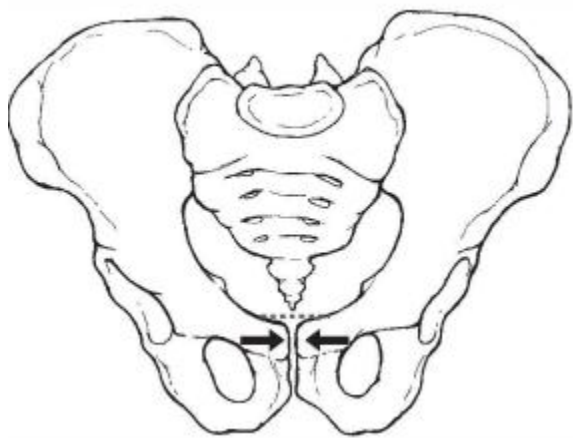
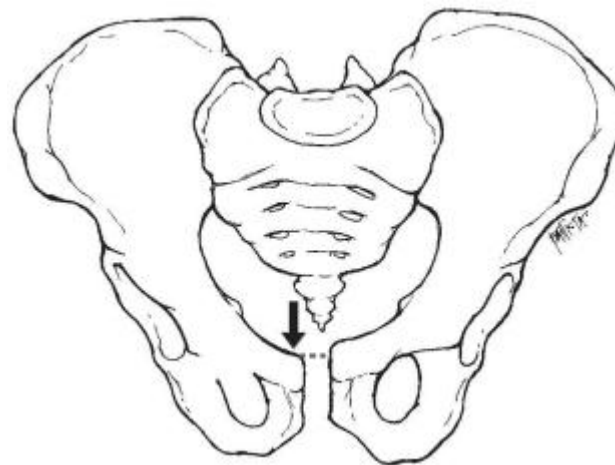
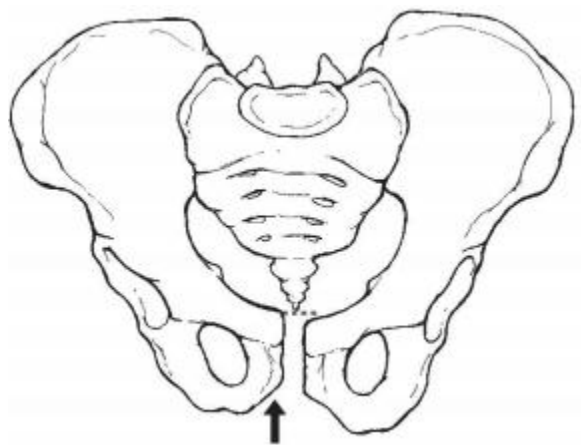
前髂调整



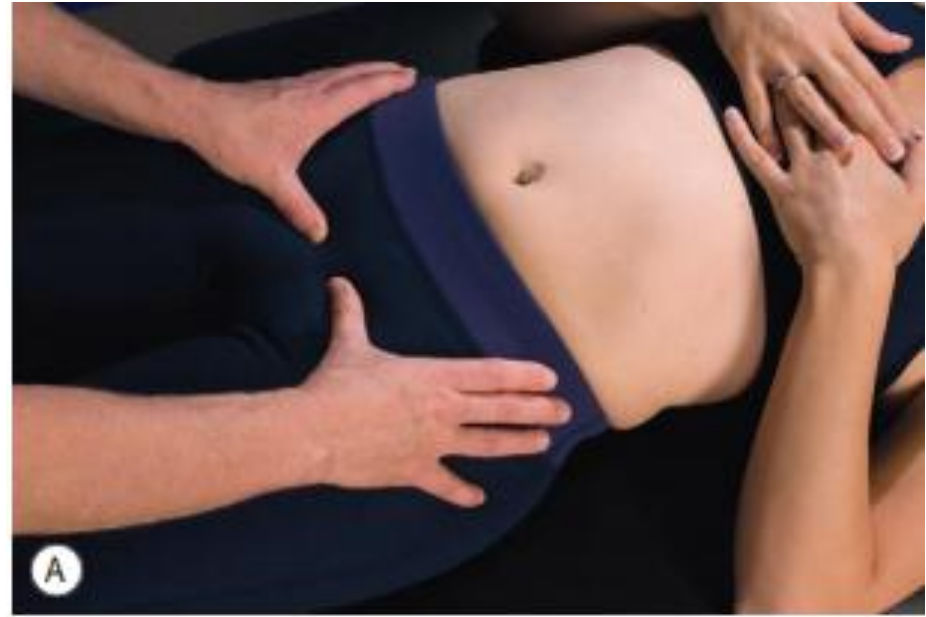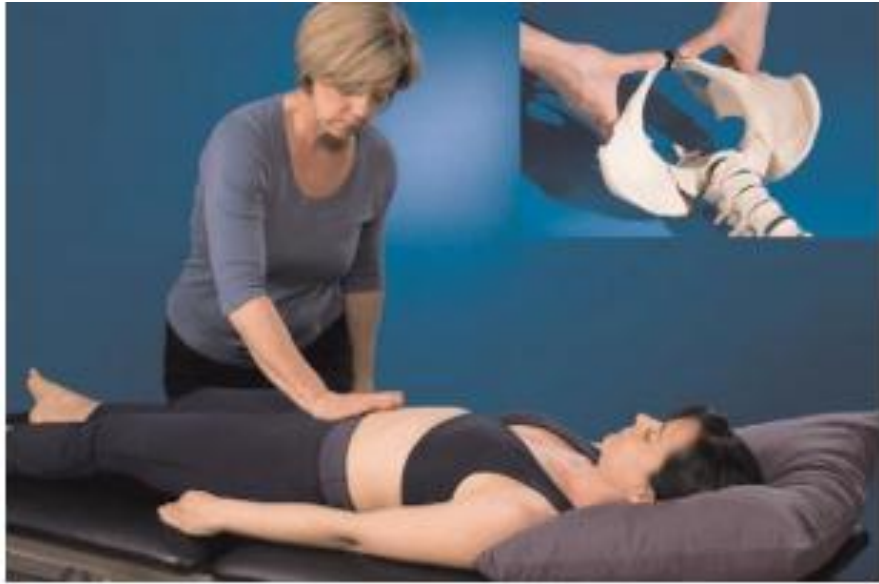后髂调整



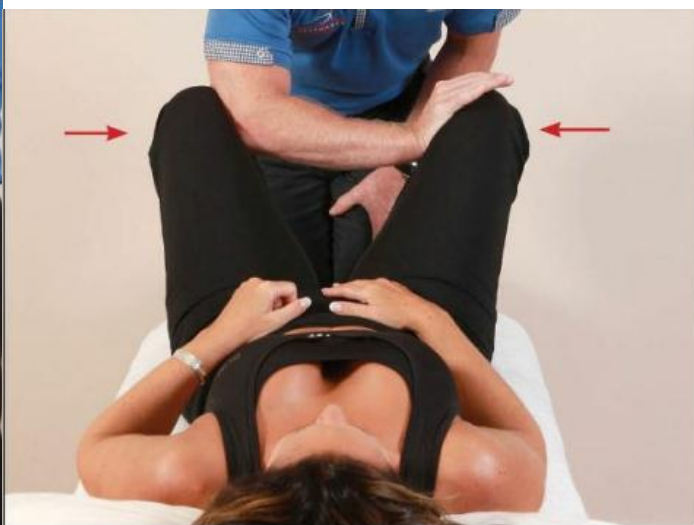
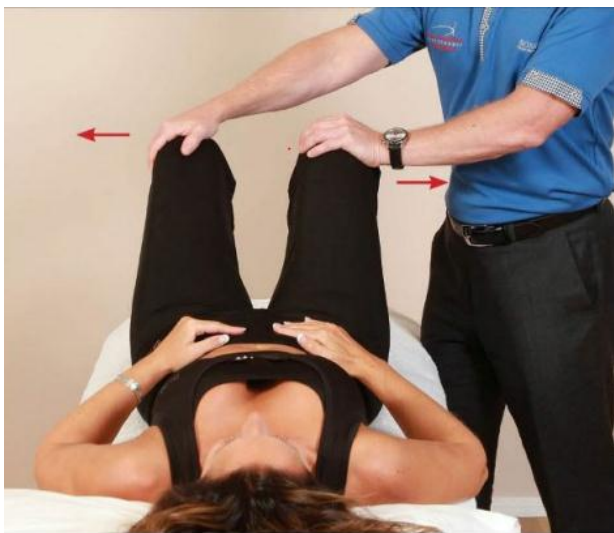
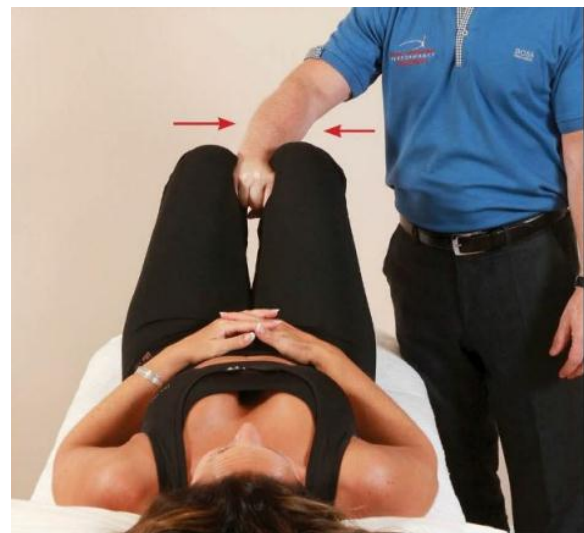
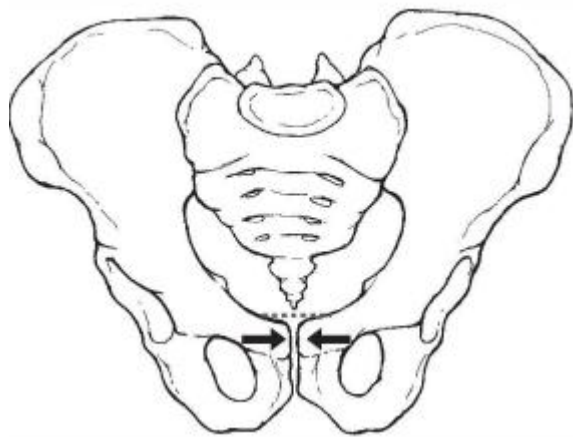
耻骨联合功能障碍



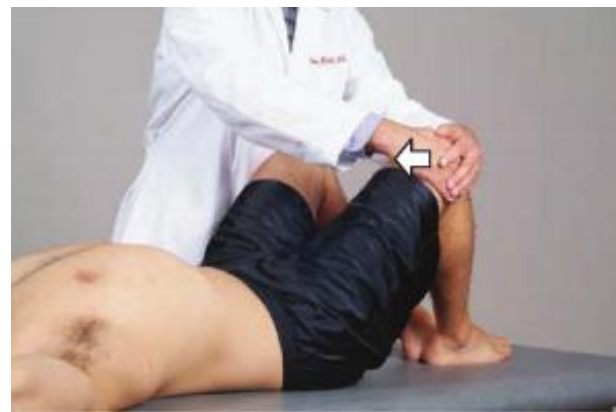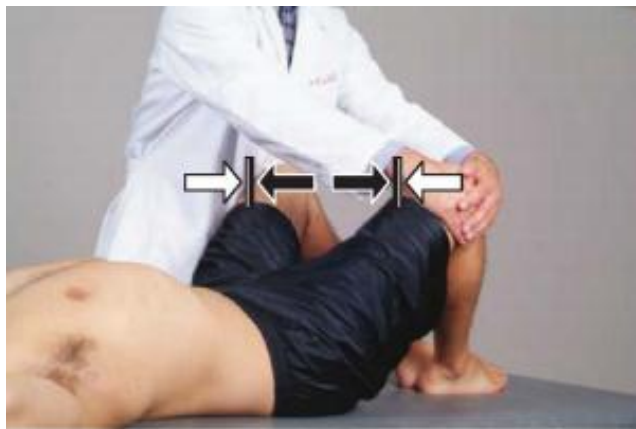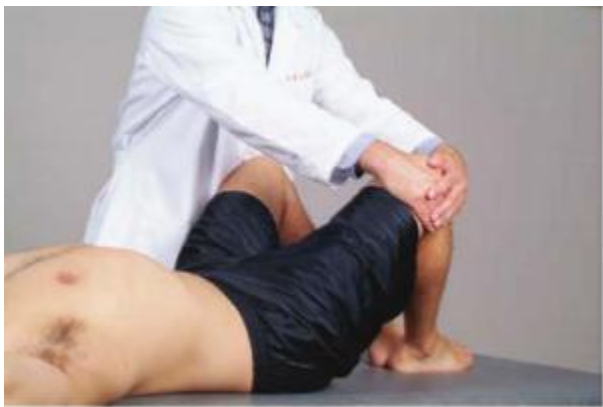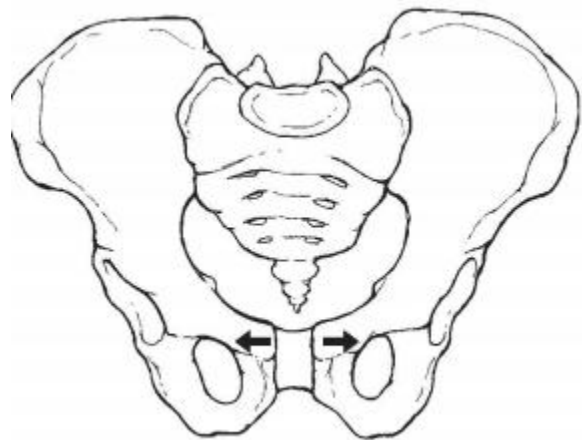
耻骨联合评估



耻骨联合关闭问题调整



耻骨联合分离处理



单侧负重

- 单侧负重对耻骨联合的影响